

Ozone Therapy in Patients with Retinitis Pigmentosa

Mirtha Copello¹, Frank Eguía², Silvia Menéndez*³, Niusdalys Menéndez¹

¹ Retinitis Pigmentosa National Reference Center. "Dr. Salvador Allende" Hospital. Calzada del Cerro Ave. and Domínguez, Cerro, Havana, Cuba

² " Ramón Pando Ferrer" Ophthalmologic Hospital. 76 St. and 31 Ave. Marianao, Havana, Cuba

³ Ozone Research Center. POBox 6880, Havana. Cuba

Abstract

Retinitis pigmentosa (RP) is characterized by progressive night blindness. The aim of this study is to determine the efficacy of ozone therapy in patients with RP. A controlled, randomized, double blind clinical trial involving 68 patients was performed. Patients were divided into 2 groups: ozone, patients were treated with ozone by rectal administration (dose=10 mg), during 15 sessions; control, as ozone group, but using oxygen. The main outcome variable was the visual field area (VFA). Results demonstrated a significant improvement (SI) in 88.2 % of patients treated with ozone in comparison with 23.5 % achieved in the control group. In the ozone group, VFA tend to stabilize beyond a mean time of 6.83 months with a loose in SI afterward. A temporal positive effect of ozone therapy, over the natural course of RP, was found. It could be useful to apply ozone therapy in the first stages of the disease and at six-month intervals in order to enhance visual capabilities in RP patients.

Introduction

Retinitis Pigmentosa (RP) is the name usually applied to a diverse group of hereditary retinal degeneration, with an overall prevalence of about 1/4000 (1) and about 1 500 000 affected people worldwide. Inheritance could be autosomal dominant, recessive, sex linked, mitochondrial, digenic or frequently isolated cases are presented. Patients complain of night blindness and progressive reduction of peripheral vision (visual field loss) with a ring scotoma, with late involvement of central vision and abnormal electroretinogram (2,3). About 50 % of patients with RP are legally blind at middle age, most of them as a result of visual field reduction (4).

Findings at ocular examination include cataracts, vitreous body alterations, pale optic disc, attenuated retinal vessels and intraretinal pigment in fundus midperiphery. These irregular black deposits of clumped pigment, called bone spicules, give the disease its name. The name

is actually a misnomer because retinitis pigmentosa is not an inflammatory process and its etiology is not well defined.

The landmark test of visual function is electroretinogram, which is usually markedly reduced, and eventually becomes non-detectable (5). Other ancillary test includes visual field and dark adaptometry. Histopathologic studies (6) have concluded that visual loss occurs because of degeneration of rods and cones photoreceptors along the retina, with quite inner retina preservation.

There have been several therapeutic trials for common forms of RP. They have included vasodilators, placental tissue, various surgical techniques, and most recently accepted, hydrolysate of yeast RNA and vitamin A supplementation (5,7), among others. Nevertheless, none of them have demonstrated definitely halt or improvement of the disease. In fact, we still need to search methods in order to introduce into photoreceptors any substance able to prolong their functional and anatomical status, or even improve it, if possible; despite of the primary genetic lesion.

Ozone (O₃) is used in several medical specialties, because of its diverse properties and safety. Several papers (8-12) reported the use of this therapy in the treatment of ocular diseases as optic neuropathies, glaucoma, central retinal vein obstructions and degenerative retinal diseases. In the case of RP, some studies (13,14) have been performed, based on several short sample, pilots, non randomized controlled trials.

Among ozone biological effects (15-21), the improvement of oxygen metabolism, increasing cell energy, the immunomodulator property and the enhancement of the antioxidant defense system could be in relation with the response achieved in patients with RP. It is possible that, rods and cones cellular membranes, because of the high concentration of non-saturated fatty acids (22,23), are susceptible to suffer free radical damage and particularly lipid peroxidation. It is known (23-25) that lipofuscin pigment, a product of lipid peroxidation, is present in very high concentration in age-related macular degeneration. Also, senile cataracts are formed secondary to oxygen-derived free radicals and subsequent oxidation of lens proteins. A strong inverse relationship between the intake of antioxidants and cataract formation is reported (26). The use of ozone therapy on age-related degenerative retinal maculopathy (12) demonstrated a lipid peroxidation decrease and an increase in superoxide dismutase, an enzyme scavenger of anion superoxide, a high toxic specie. By this way, increasing antioxidant defense system, ozone is capable to minimize the damage produced by lipid peroxidation.

Taking into account the ozone biological effects and that treatments attempted for RP have been unsuccessful, the aim of this study is to assess the effect of ozone therapy on patients with typical RP.

Materials and Methods

Patients and Treatment

The study was carried out in the Retinitis Pigmentosa National Reference Center (RPNRC), at "Salvador Allende" Hospital, during January 1999 to June 2000. Our main inclusion criterion was patients with the typical form of RP (not associated). It was a prospective, randomized, controlled, double blind clinical trial.

Sixty eight patients were divided into 2 groups: Control (oxygen) and Ozone groups and were

followed up during 12 months. Both groups were homogenous with respect to: age, sex, mode of inheritance and stage of the disease; all of them important variables on RP course. Patients can not receive any other additional treatment at the beginning or during the course of the study (included any vitamin or vasodilators supplementation, magnetotherapy, electric stimulus). Patients who were selected signed the informed consent, after complete explanation of the purpose and characteristics of the study. The protocol was approved by the Ethics Committee of the Scientific Council of the RPNRC, according to the Declaration of Helsinki.

In the ozone group, 34 patients received, daily, 200 ml of a gas mixture composed of medical oxygen (O_2) and O_3 (generated by an OZOMED equipment, Havana, Cuba), with an O_3 concentration of 50 mg/l, representing a dose of 10 mg of O_3 , during 15 sessions. In the control group (oxygen), 34 patients received, daily, 200 ml of medical O_2 . The route of administration was rectal, using a plastic catheter, previous lubricant ointment application. Physicians and examiners that were in charge of patient evolution did not know which group each patient belonged to, neither the patients. Data monitoring and Safety Committee delegates, not related to the study, kept surveillance over possible side effects in all patients (results not shown on this paper). Treatment could be stopped if any undesirable event occurred in at least 20 % of the ozone group.

Measurements

Main visual variable outcome was visual field area (VFA). It was measured using a Kinetic Goldmann Perimetry (Karl Zeiss), defining the area of the isopter explored with a white V4 e stimulus. The isopter area was measured in mm^2 , by planimetric calculation and by outcome analysis, also on percentage of initial (basal) VFA.

To all patients, prior the treatment, an initial (basal) visual field was performed. Then, the visual field measurements were repeated monthly, after ozone or oxygen treatment, until a year. On each patient, 13 visual field measurements (one basal and twelve for follow-up) were performed. The planned figure, in order to perform the test in all sample, was 884 visual field measurements. It was fulfilled in 94.9 % (839 of 884), a figure considered acceptable.

Before beginning the study, each selected patient was instructed on the performing of the test and underwent two previous visual field test to be familiarized with it. Examiner and equipment were always the same and examiner was blinded. Also, prior the treatments, to all patients, an initial Snellen best corrected visual acuity was performed.

Significant improvement (SI) was only assessed if an improvement of ≥ 25 % of basal V4 e isopter VFA was presented in at least two monthly consecutive exams. Patients who did not undergo this variation would not be considered as improved. Nevertheless, in each patient, VFA variation was taken in account for statistical analysis, despite it could be a significant improvement or not. and maintained in 2 consecutive monthly exams.

Stage of the disease was determined, based on the visual field criteria of O. Peláez RP classification (4). It is classified in 4 stages: early stage of the disease, when patients where on stage I and II and late stage when patients where on stage III and IV. Thus, were selected nine patients on each stage (I, II and III) of the disease for each group, and seven patients for stage IV.

Statistical analysis

Statistical analyses were performed using Foxpro 2.6 (Microsoft, Seattle, Wa.) for data collection. Processing was performed with PC SAS 6.12 (Cary, NC.) Descriptive statistic was used to summarize all continuous variables and Student's t test to compare variables distribution at baseline. One way ANOVA was used to compare, differences in VFA, among groups and intra-groups. Variation of VFA was determined by percentage of change related to basal VFA, and also in mm². Frequency of significant improve (SI) patients among groups was compared using Fisher Exact probability test. Mann-Whitney non-parametric test was used to compare the change of VFA from baseline to one-year follow-up, taking into account the stage of disease stratification. Time for lost of SI was analyzed by Kaplan-Meier method. For baseline comparison, a confidential interval (CI) of 95 % was defined. A P value of 0.05 or less was considered statistically significant.

Results

Baseline characteristics are shown in Table I. As the result of pairing the groups, both groups were homogenous on size and sex frequencies, with no differences concerning age distribution (p= 0.21) and clinical variables (visual acuity and visual field area), based on the stage of the disease. The mean values for visual acuity and for visual field area are equivalent to a patient with a moderate development of the disease. That is determinant in order to avoid the possible influence in our results, of extremes stages of the disease, where patients are prone to very different responses to treatment.

Table I: Demographic and Clinical Baseline Data.

Characteristics	Ozone	Control	p Value
Number of patients	34	34	-
Sex (Female - %)	52.9	52.9	-
Age (years)	35.62 ± 11.31	39.31 ± 9.51	0.21
VA (Snellen)	0.41 ± 0.10	0.48 ± 0.16	0.32
VFA (mm ²)	423.06 ± 58.17	468.71 ± 70.23	0.45

Data are mean ± SD. VA - Visual Acuity, VFA - Visual Field Area.
Unpaired Student's t Test

Figure 1 represents the visual field of a patient with RP treated with ozone. A significant improvement of ≥ 25 % of basal V4 e isopter VFA was achieved after the treatment.

Basal VF

Evolution

Figure 1: Example of a significant visual field improvement of a patient treated with ozone.

There was achieved three times more improved patients in ozone group (88.2 %) than in control group (23.5 %) (see Table II). This difference between groups was significant ($p < 0.05$) Logically, differences related to worsened or stable patients between groups were also significant. The quantitative analyses of the improvement demonstrated an almost three-fold significant improvement in amplitude, over basal VFA, on the ozone group than on control group ($p = 0.009$). Variance analyses also indicated a greater variation on VFA in the ozone group than in the control group, with significant difference between both groups ($p = 0.0006$). A single group analysis showed that the quantitative improvement on VFA over basal was statistically significant in the ozone group ($p = 0.006$), but not in the control group ($p = 0.3$)

Table II. Post-treatment improvement. General Aspects.

Characteristics	Ozone	Control	P Value
Significant Improved Cases number of patients (%)	30 (88.2)	8 (23.5)	0.003
No Change/Worsened number of patients (%)	4 (11.8)	26 (74.4)	0.005
Improvement Mm^2 (Mean)	32.9	11.30	0.009
Variance	130.05	44.69	-
P	4.163	1.421	0.0006
	0.006	0.3	-

Unpaired Student's t Test

Patients with early stages (ES) of the disease were more likely to undergo a greater improvement than late stage (LS) patients (see Table III). Patients treated with ozone, at ES achieved 64.7 % of SI on VFA, compared with 29.4 % at LS. This difference was significant ($p = 0.0006$). This finding remained when the control group was analyzed, but the difference was not so significant ($p = 0.05$). Mean improvement was two times greater in ES patients than

LS (44.7 vs. 21.8 %) in the ozone group. Non-parametric statistics (Mann-Whitney test) showed also the significant difference of the quantitative improvement between early and late stages of the disease. Despite among controls also existed more improvement on VFA in ES patients, in comparison with LS patients (18.2 % vs. 11.2 %), this difference lacks of statistical significance.

Table III: Improvement and stage of the disease.

Characteristics Groups			
Significant Improved Cases	Ozone		
	Control		

Mean Improvement of VFA

Ozone

Control

Early Stages Late Stages

64.7 % 29.4 %

$X^2 = 4.556; df=1; p=0.0006$

17.6 % 5.9 %

$X^2 = 3.903; df=1; p=0.05$

47.7 % 21.8 %

$U_{(88)} < U_{0.05(2)} = 80$

18.2 % 11.2 %

$U_{(25)} < U_{0.05(2)} = 27$

For both Control and Ozone Groups: Early Stages: I and II: 18 patients; Late Stages: III and IV: 16 patients. Chi-Squared Test and Mann-Whitney Test

Table IV shows that in the ozone group, at the first semester of follow-up, there were almost four times more patients with an SI on VFA (79.4 %) than in the second semester (20.6 %),

with significant differences ($p=0.0001$) between them. However, in control group, despite a two times more improved patients in the first semester (20.6 %) than in the second one (11.8 %), the differences were not significant ($p=0.2$).

Table IV: Improved cases by semester.

Semesters

Groups

Ozone

Condition

Significant Improved Cases

First Second
79.4 % 20.6 %

	$X^2=64.23; df=1; p=0.0001$		
Control			


Significant Improved Cases

20.6 % 11.8 %

$X^2=6.67; df=1; p=0.20$

Figure 2 expresses the probability of maintaining the VFA improvement achieved with the treatments. The ozone group maintained, for longer time, the treatment response in comparison with the control group. It is not until approximately 7 months (mean: 6.83 months) when more than a half of the sample (ozone group) lost the improved condition. At month 10, there was less than 20 % of success (11.8 %). At month 11, there was unlikely that a patient could be improved by the effect of a single treatment. Control group behavior was very different. From month two on, there is less than 20 % of probability to be significantly improved, and at month eight, there is a null probability of being improved. The control response, as expected, was very unstable and short.

Survival Probability



0.9
0.8
0.7
0.6 Ozone Group
0.5 6.83 months:
0.4
0.3 < 50 % of Sample Improved
0.2
0.1 Control Group
0

1 2 3 4 5 6 7 8 9 10 11
Months

Figure 2. Kaplan -Meier survival analysis of probability of the significant improvement.

Results regarding quantitative aspects of VFA improvement over time are shown in Table V. Ozone group improved 30.8 % of area over basal VFA in the first semester, with a maximum of 33.6 % at month three post-treatment. In the second semester, only an improvement of 18.9 % was achieved, with a significant difference between both semesters ($p=0.0001$). Also, at first semester, a two-fold improvement by meridian per month was achieved, in comparison with second semester (2.71 vs. 1.13 $\text{mm}^2/\text{meridian}/\text{month}$). In control group, the differences in the mean VFA improvement, between both semesters were not statistically significant. Comparison between ozone and control groups, in both semesters, always showed significant differences, regarding the mean VFA improvement (first semester, $p=0.0005$) and second semester, $p=0.03$) and that obtained by the analysis of meridian.(first semester, $p=0.0004$ and second semester, $p=0.008$) (not shown on Table V).

Table V: Quantitative improvement of VFA by semester.		Semesters	
Groups	Condition		
Ozone	Mean VFA Improving (%)		
Control	Mm ² /Meridian/Month Improvement		
	Mean VFA Improving (%)		
	Mm ² /Meridian/Month Improvement		

First Second

30,8 % 18,9 %

$X^2=13,18$; $df=1$; $p=0,0001$ (†)

2.71 1.13

$T = 4.06$; $df=5$; $p= 0.0011$

8.9 % 6.9 %

$X^2=2.23$; $df=1$; $p=0.09$ (†)

0.96 0.54

$T = 1.71$; $df=5$; $p= 0.10$

(†) Fisher's Exact test

A comparison of the outcome, during a follow-up of one year, is shown in Figure 3. Six months after ozone therapy, the VFA mean increase was 27.7 % (540,28 mm^2) over basal measurement, however, control group had a decrease of 16.9 % (389,48 mm^2) from basal VFA. At this moment of follow-up, there was a significant difference in VFA between both groups ($p= 0.008$). At month twelve, ozone group still had an increase of 8.0 % (457,37 mm^2) over basal VFA and

control group had lost 24.2 % of its VFA, with a mean VFA of 355.19 mm², without statistically significant differences between groups (p=0.06).

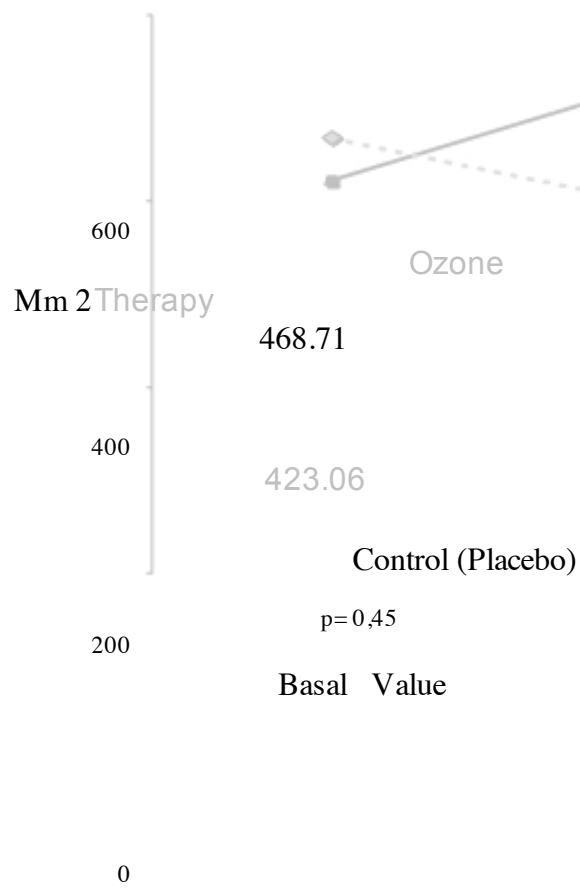


Figure 3. Visual field area outcome for both groups, during a follow-up of one year.

Discussion

In this study, ozone treatment had a positive influence on patients with RP, improving the natural campimetric outcome of the disease. Patients treated with ozone had a better campimetric

outcome than controls, with a greater and long-lasting visual field variation toward improvement.

Despite ozone mechanism of action in RP is not yet clear and completely theoretical, the definite differences achieved with respect to control group, make us reject the possibility of a placebo-like response. Thus, control group developed a short duration and reduced response to shamed treatment, as expected in a placebo response.

Also, despite natural great variation of visual field tests in RP patients (up to 20 %), immediate/mediate response to ozone treatment was always greater in magnitude than the natural outcome range. However, in control group, response did not differ from natural variation. Our study was designed attending to this particular situation. As our main outcome variable (visual field) is a subjective measurement, submitted to inter-examination variations, we tried first to train patients on the performance of the test, in order to reduce artificial underscore or over-response at first exam, due to misunderstanding of the test. In patients suffering of advanced chorioretinal dystrophies, a range of variation between exams (from 10 to 16 %) had been demonstrated (27,28).

On regular RP patient, a yearly lost, up to 16 % of residual VFA, is expected (29). In a study (30) of the disease natural history, twenty-one percent of patients at a year of follow-up was

worsened. In patients treated with ozone, at a year of follow-up, only four patients (11.8 %) had lost VFA from basal values, and mean VFA on this group still showed 8.0 % of improvement.

As demonstrated in our study, treatment response lost its significance about six month's follow-up. It seems to be that ozone effectiveness is self-limited, because the sample was homogenous in age and stage of the disease. Same results were achieved in a controlled clinical trial using ozonized blood, as a treatment for RP (31). Visual field area, 6 months after the ozone treatment, improved in 46.7 % of patients and were not observed in 91.9 % of patients one year after the treatment. In a study (32) of the clinical evolution of 20 patients that have been treated (between 5 and 10 years) with repetitive cycles of ozone therapy (twice a year), 70 % of patients maintained a visual field improvement, during the follow-up. The rest of the patients maintained their visual field the same as the initial value, without worsen the disease. Thus, we have the opinion that repetition of ozone treatment could be an option for these patients, taking into account that it is a safe (16) and non-invasive therapy.

In another recent study was demonstrated that the half-life of Goldmann visual field on a RP patient might be of about 6.8 to 7.3 years (33). So it is very important on those patients any improvement of VFA, despite a little it could be. If we could be able to delay these yearly visual field lost (as shown in this study), maybe visual field could be also save.

Nevertheless, more studies have to be done in order to prove the ozone effectiveness, since some researchers in the field of RP believe that ozone has no benefit in the treatment of this disease (34,35) and others yes (36,37).

Why can ozone treatment be useful on RP? There are two main factors that can be modulated by ozone actions. First, despite attenuation of retinal vessels on RP, there is a relative inner retinal architecture "preservation" until late stages of disease (38,39); and in relation to hemodynamic retinal aspects, although there is a reduction of blood flow in the order of 78 %,

vascular response to hypoxia is functional until advanced stages (40) In the other hand, oxidative damage of photoreceptors is a nonspecific mechanism, common to several degenerative diseases of the retina, because of the high concentration of non-saturated fatty acids on rods and cones cellular membranes. These elements can suffer peroxydation, and its end-products could be toxic to retina.

Ozone treatment has the potential capability of modulate all these factor and probably leading to a re-adjustment of metabolic pathways of photoreceptors, promoting an improvement on visual response. Also, ozone has immunological properties, and on certain patients with RP, it has shown activity of anti-retinal antibodies (41) in which its real role and mechanism of action are yet not understood. It could be another possible mechanism of ozone action, taking into account its immunomodulator properties (42).

Despite the clinical trial designed for this study, it has several limitations mainly related to sample size and subjective nature of the main outcome variable. Also, the heterogeneity of the

pathogenic damage of the disease and the wide clinical spectrum of RP (43) turn into a very difficult task to afford a study with definitive results.

Even that, our results are encouraging. We think that large scale, multicenter clinical trials could be very useful to state a confidential conclusion about the real role of ozone as an option for the treatment of patients with RP.

Conclusions

Ozone therapy seems to be effective in the management of selected cases with common forms of RP. In patients treated with ozone, there was a short-term improvement on VFA, mainly restricted to the first six months after therapy. Stage of the disease appears to have a markedly influence on treatment response, seems to diminish the therapeutic effect of ozone and decrease the frequency and the magnitude of VFA. Although not analyzed on this study, semestral ozone therapy treatments are needed, in order to preserve visual field improvements and to decrease the rapidity of deterioration that is now anticipated if this type of therapy has not been administered. Despite the short size of our sample and the subjective character of the VFA measurement, we think that ozone therapy is a real and effective possibility of noninvasive treatment in patients, in which other alternatives are not very safe or with few positive results. Thus, we encourage continuing the research on the therapeutic capabilities of ozone in RP and suggesting a deeper and long-scale study.

Key Words

Ozone; retinitis pigmentosa; visual field; double blind clinical trial; lipid peroxidation.

References

1. Heckenlively, J.R. Retinitis Pigmentosa. (Philadelphia, USA: JB Lippincott; 1988).

2. Berson, E.L. "Retinitis Pigmentosa and allied diseases" in: Albert, D.M., Jacobietz, F.A. eds. Principles and Practice of Ophthalmology: Clinical Practice, Vol. 2 (Philadelphia, USA: WB Saunders, 1994), p:1214-1237.
3. Berson, E.L. "Retinitis Pigmentosa. The Friedenwald Lecture", IOVS, 34: 1659-1676 (1993).
4. Peláez, O. Retinosis Pigmentaria. Experiencia Cubana (La Habana, Cuba: Ed. Científico-Técnica, 1995).
5. Berson, E.L. "Retinitis Pigmentosa Update" (abstract), Proceedings of the AAO Annual Meeting, p.119 (1998).
6. Verhoeff, F.H. "Microscopic observations in case of Retinitis Pigmentosa", Arch. Ophthalmol., 5:392-407 (1931).
7. Berson, E.L. "A randomized trial of Vitamin A and Vitamin E supplementation for Retinitis Pigmentosa", Arch. Ophthalmol., 11(6):761-772 (1993).
8. Triana, I., Menéndez, S., Peláez, O., Copello, M. "La ozonoterapia en el campo de la oftalmología", Rev. Cubana de Oftalmología, 2(3):168-172 (1990).
9. Santiesteban, R., Menéndez, S., Francisco, M., Luis, S. "La ozonoterapia en la disfunción del nervio óptico". in: Proceedings of the Eleventh Ozone World Congress Vol. International Ozone Association Ed. (San Francisco, USA: Port City Press, 1993), p. M-4-1- M-4-9.
10. Menéndez, S., Ferrer, L., Santos, D., Pérez, Z. "Ozonoterapia y magnetoterapia: nuevos métodos en la rehabilitación del paciente portador de glaucoma crónico simple", in: Proceedings of the 12th Ozone World Congress Vol. 3 International Ozone Association Ed. (Lille, France: Insta Print S.A. Tours, 1995), p. 99-106.
11. Ferrer, L., Santos, D., Pérez, Z., Fernández, I., Varela, F., Menéndez, S. "Ozono-magnetoterapia como terapéutica en el paciente portador de glaucoma crónico simple. Experiencia de 10 años de trabajo" (abstract), in: Libro de Resúmenes del 3er Simposio Internacional de Aplicaciones del Ozono (C. Habana, Cuba: Editorial CENIC, 2000), p. Oz-11.
12. Riva Sanseverino, E., Meduri, R.A., Pizzini, A. "Effects of oxygen-ozone therapy on age-related degenerative retinal maculopathy", Panminerva Med. 32: 77-84 (1990).
13. Menéndez, S., Peláez, O., Gómez, M., Copello, M. "Aplicación de la ozonoterapia en la retinosis pigmentaria", Rev. Cubana de Oftalmología, 3(1): 35-39, (1990).
14. Copello, M., Eguía, F., Menéndez, N., Trigoura, D., Fernández, G., Menéndez, S. "Ozonoterapia en la retinosis pigmentaria y su influencia en la respuesta terapéutica" (abstract), in: Libro de Resúmenes del 3er Simposio Internacional de Aplicaciones del Ozono (C. Habana, Cuba: Editorial CENIC, 2000), p. Oz-30.
15. Viebahn, R. The use of ozone in Medicine, 3rd English edition (Iffezheim, Germany: ODTREI-Publishers, 1999), p.95-119.
16. Bocci, V. "Ozone as a bioregulator. Pharmacology and toxicology of ozonotherapy today", Journal of Biological Regulators and Homeostatic Agents, 10(2/3):1-53 (1997).

17. Barber, E., Menéndez, S., León, O.S., Barber, M.O., Merino, N., Calunga, J.L., Cruz, E., Bocci, V. "Prevention of renal injury after induction of ozone tolerance in rats submitted to warm ischemia", *Mediators of Inflammation*, 8:37-41 (1999).
18. Hernández, F., Menéndez, S., Wong, R. "Decrease of blood cholesterol and stimulation of antioxidative response in cardiopathy patients treated with endovenous ozone therapy", *Free Rad. Biol. Med.*, 19:115-119 (1995).
19. León, O.S., Menéndez, S., Merino, N., Castillo, R., Sam, S., Pérez, L., Cruz, E., Bocci, V. "Ozone oxidative preconditioning: a protection against cellular damage by free radicals", *Mediators of Inflammation*, 7:289-294 (1998).
20. Peralta, C., León, O.S., Xaus, C., Prats, N., Jalil, E.C., Planell, E.S., Puig-Parellada, P., Gelpí, E., Roselló-Catafau, J. "Protective effect of ozone treatment on the injury associated with hepatic ischemia-reperfusion: antioxidant-prooxidant balance", *Free Rad. Res.*, 31:191-196 (1999).
21. Candelario-Jalil, E., Mohammed-Al-Dalain, S., León, O.S., Menéndez, S., Pérez-Davidson, G., Merino, N., Sam, S., Ajamieh, H.H. "Oxidative preconditioning affords protection against carbon tetrachloride-induced glycogen depletion and oxidative stress in rats", *J. Appl. Toxicol.*, 21 (2001) (in press).
22. Gerster, H. "Review: antioxidant protection on ageing macula", *Age Ageing*, 20:60-69 (1991).
23. Katz, M.L., Robinson, W.G., Dratz, E.A. "Potencial role of aotoxidation in age changes in the retina and retinal pigment epithelium of the eye", in: *Free Radicals in Molecular Biology, Aging and Disease*, Armstrong, D., Sohol, R.S., Cutler, R.G., Slater, T.F. eds. (New York, USA: Raven Press, 1984), p.163-180.
24. Knight, J.A. "Diseases related to oxygen-derived free radicals", *Annals of Clinical and Laboratory Science*, 25(2): 11-121 (1995).
25. Young, R.W. "Solar radiation and age-related macular degeneration", *Surv. Ophthalmol.*, 32:252-269 (1988).
26. Jacques, P.F., Chylack, L.T., Jr. "Epidemiologic evidence of a role for the antioxidant vitamins and carotenoids in cataract prevention", *Am. J. Clin. Nutr.*, 53:352S-355S (1991).
27. Ross, D. et al. "Variability of visual field measurements in normal and patients with Retinitis Pigmentosa", *Arch. Ophthalmol.*, 102:1004-1010 (1984).
28. Alemán, T. et al. "Estudio de la variabilidad del campo visual y test de sensibilidad al contraste en pacientes con Retinosis Pigmentaria", Free paper presented in V National Workshop of Retinitis Pigmentosa, Dec. 1995.
29. Humphries, P. et al. "On the molecular genetic genetics of Retinitis Pigmentosa", *Science*, 256: 804-808 (1992).
30. Berson, E. L. et al. "Natural course of Retinitis Pigmentosa over a three-year interval", *AJO*, 99(3):240-251 (1985).
31. Moreno, N., Peláez, O., Alemán, T., Barceló, C. "Controlled clinical trial on the use of

ozonized blood as a treatment for retinitis pigmentosa" (abstract), in: Proceedings of the 2nd International Symposium on Ozone Applications, J. Moleiro, S. Menéndez eds. (La Habana, Cuba: Inst. Superior Politécnico José A. Echevarría, 1997), p. 37.

32. Copello, M., Menéndez, S., Horrach, I., Betancourt, J. "Ten years study in patients suffering from retinitis pigmentosa and treated with repeated cycles of ozone therapy", in: Proceedings of the 2nd International Symposium on Ozone Applications, J. Moleiro, S. Menéndez eds. (La Habana, Cuba: Inst. Superior Politécnico José A. Echevarría, 1997), p. 36.
33. Grover, S., Fishman, G.A., Anderson, R.J. "Rate of visual field in Retinitis Pigmentosa", *Ophthalmology*, 104:460-465 (1997).
34. Berson, E.L., Remulla, J.F.C., Rosner, B., Sandberg, M.A., Weigel-Franco, C. "Evaluation of patients with retinitis pigmentosa receiving electric stimulation, ozonated blood and ocular surgery in Cuba", *Arch. Ophthalmol.*, 114:560-563 (1996).
35. Welebwe, R.G. "The Cuban experiment: false hope for a cure for retinitis pigmentosa", *Arch. Ophthalmol.*, 114:606-607 (1996).
36. Marmer, R., Parks, S. "Ozone treatment in retinitis pigmentosa: effect on color perception and blood gasses", *Ann. Ophthalmol.*, 30(3):161-163 (1998).
37. Marmer, R., Parks, S. "Ozone treatment in retinitis pigmentosa: effect on photo stress and contrast sensitivity", *Ann. Ophthalmol.*, 30(3):164-166 (1998).
38. Marshall, J., Heckenlively, J. *Pathological findings and putative mechanisms in Retinitis Pigmentosa* (Philadelphia, USA: JB Lippincott, 1988), p: 37-63
39. Lu, Z. "Histopatology of bone-spicule pigmentation in Retinitis Pigmentosa", *Ophthalmology*, 162:805-816 (1995).
40. Grunnwald, J.E. "Retinal Hemodynamics in Retinitis Pigmentosa", *AJO*, 122 (4):502-508 (1996).
41. Winstean, G.W., Maumenee, A.E., Hyvarinen, L. "On the pathogenesis of the Pigmentary Retinitis", *Ophthalmology*, 62:82 - 97 (1971).
42. Bocci, V. "Ozone: a mixed blessing", *Forsch Komplementärmed*, 3:25-33 (1996).
43. Fulton, W. How shall research in the treatment of Retinitis Pigmentosa proceed?, *Arch Ophthalmol*, 111(6):754-756 (1993).